

Available online at [www.sciencedirect.com](http://www.sciencedirect.com)

ScienceDirect

journal homepage: [www.elsevier.com/locate/burns](http://www.elsevier.com/locate/burns)

## Pirfenidone increases the epithelialization rate of skin graft donor sites

Gabriel Ángel Mecott-Rivera <sup>a,\*</sup>, Jorge Alejandro Aguilar-Baqueiro <sup>a</sup>,  
Stephano Bracho <sup>a</sup>, Ivette Miranda-Maldonado <sup>b</sup>,  
Rodolfo Franco-Márquez <sup>b</sup>, Yanko Castro-Govea <sup>a</sup>,  
Edgar Gerardo Dorsey-Treviño <sup>a</sup>, Mauricio Manuel García-Pérez <sup>a</sup>

<sup>a</sup> Department of Plastic, Aesthetic, and Reconstructive Surgery, University Hospital “Dr. José E. González”, Universidad Autónoma de Nuevo León, 64460, Monterrey, Mexico

<sup>b</sup> Department of Pathology, Faculty of Medicine, Universidad Autónoma de Nuevo León, 64460, Monterrey, Mexico

### ARTICLE INFO

#### Article history:

Accepted 19 July 2018

Available online xxx

#### Keywords:

Partial-thickness burns

Burns

Pirfenidone

Epithelialization

Wound care

### ABSTRACT

**Background:** Improving epithelialization of donor sites of split-thickness skin grafts (STSG) is extremely important in burned patients. We aimed to assess the efficacy of pirfenidone, a drug with anti-inflammatory, antifibrotic, and antioxidant effects, to accelerate wound healing. We hypothesized that pirfenidone accelerates the epithelialization rates in donor sites.

**Methods:** We included 28 patients requiring STSGs with donor sites of at least  $7.5 \times 10$  cm. After harvesting, the donor sites were randomly treated with either non-adherent gauze or topical pirfenidone and covered with non-adherent gauze. To assess epithelialization, biopsies were taken at day 7 and 10 on the pirfenidone group, and at day 10 on the control group. Percentage of epithelialization was assessed on the same days through clinical photographs. The pathologists and the clinical observer were blinded to the group and timepoint of the samples.

**Results:** 24 patients were included in the study, with a median age of 21(5–73) for control group and 28(9–61) for pirfenidone. The thickness of epithelium was  $75.10 \pm 60 \mu\text{m}$  at day 10 for the control group; and  $98.21 \pm 6 \mu\text{m}$  at day 7, and  $108 \pm 22 \mu\text{m}$  at day 10 for the pirfenidone group ( $p < 0.05$ ). Epithelialization rate was  $83.58 \pm 14.09\%$  at day 10 for the control group; and  $98.7 \pm 1.8\%$  at day 7, and  $99.5 \pm 1.6\%$  at day 10 for the pirfenidone group.

**Conclusions:** Pirfenidone is efficient in reducing the healing times when applied in STSG donor sites, at both days 7 and 10.

© 2018 Elsevier Ltd and ISBI. All rights reserved.

\* Corresponding author at: Department of Plastic, Aesthetic, and Reconstructive Surgery, Universidad Autónoma de Nuevo León, Francisco I. Madero y Av. Gonzalitos s/n, Mitras Centro, 64460, Monterrey, Nuevo León, Mexico.

E-mail addresses: [gabriel.mecottrv@uanl.edu.mx](mailto:gabriel.mecottrv@uanl.edu.mx) (G.Á. Mecott-Rivera), [drjorge.ab@hotmail.com](mailto:drjorge.ab@hotmail.com) (J.A. Aguilar-Baqueiro), [braruiz.emm@gmail.com](mailto:braruiz.emm@gmail.com) (S. Bracho), [imiranda77@hotmail.com](mailto:imiranda77@hotmail.com) (I. Miranda-Maldonado), [rancid2703@gmail.com](mailto:rancid2703@gmail.com) (R. Franco-Márquez), [goveayanko@hotmail.com](mailto:goveayanko@hotmail.com) (Y. Castro-Govea), [dorsey.trevino@gmail.com](mailto:dorsey.trevino@gmail.com) (E.G. Dorsey-Treviño), [drmauriciogarcia@gmail.com](mailto:drmauriciogarcia@gmail.com) (M.M. García-Pérez).

<https://doi.org/10.1016/j.burns.2018.07.007>

0305-4179/© 2018 Elsevier Ltd and ISBI. All rights reserved.

## 1. Introduction

Skin grafting is one of the oldest and most common procedures in plastic surgery, and the treatment of skin donor sites has been an important issue for decades [1]. Split thickness skin grafts (STSGs) contain the entirety of the epidermis and a variable amount of dermis depending on the thickness of the harvested graft [2]. This procedure creates a wound in the donor site that is similar to a superficial, second-degree burn, which usually takes between 14 and 21 days to spontaneously heal with relatively inconspicuous scarring [3].

It is important to treat the donor sites as any other injury because they are often more painful than the original wound where the graft is applied [2]. STSG donor sites can develop complications such as poor scar formation, with changes in skin color and texture [4]. Improved resuscitation and treatment for burn patients have led to an increased survival for patients with large burned areas, which may involve most of the entire body surface. In some patients, it is necessary to harvest subsequent skin grafts from the same donor site, which is limited by skin quality and healing times; this process can consume a considerable amount of time and may increase the risk of bacterial contamination, thereby, increasing the morbidity and mortality of these patients [3,5]. Hence, it is important to reduce the time between grafting.

Based on these characteristics, the foremost objectives of an adequate treatment of the donor site include relieving pain, accelerating healing, and preventing infection. Multiple dressings have been developed to treat donor sites, of which the paraffin impregnated gauze is the simplest and the most widely used occlusive dressing [2]. In this study, we focused on healing time because it is critical for higher morbidity patients (e.g., patients with large burns).

Reported epithelialization times of STSG donor sites vary among studies, which is probably because of numerous unreported variables and factors affecting the healing rates. The reported mean time for epithelialization for a STSG donor site that is treated with paraffin impregnated gauze is 12.79 days [6]. Other more modern dressings, such as hydro-colloid, transparent film, and calcium alginate dressings, have demonstrated faster healing times [6]. In general, moist dressings are more effective in promoting reduced healing times and pain relief, making them the preferred choice for most cases [7].

Although modern dressings have shown substantial improvements, new potential treatments and technologies frequently emerge. Pirfenidone (5-methyl-1-phenyl-2-(1H)-pyridine) is a synthetic pyridine that was created by Gadekar as a compound with analgesic, antipyretic, and anti-inflammatory properties [8]. The most common use of pirfenidone is to treat idiopathic pulmonary fibrosis. However, this substance has been reported to act by modulating certain cytokines, such as TGF- $\beta$ , TNF- $\alpha$ , epidermal growth factor and platelet derived growth factor, to reduce the inflammatory response [8,9].

In Mexico, pirfenidone exists in an 8% gel form, with the commercial name of Kitoscell<sup>®</sup> (CellPharma, Mexico City, Mexico). The principal use of Kitoscell<sup>®</sup> is for treating and preventing pathological scar formation [10]. However,

Kitoscell<sup>®</sup> may also be useful in the treatment of acute wounds because it reduces the inflammatory response, thereby controlling secondary edema and promoting a better blood supply. These effects may synergistically act by regulating wound healing and collagen production [11]. Considering the antifibrotic, anti-inflammatory, and antioxidant effects of Kitoscell<sup>®</sup>, we decided to evaluate its efficacy in accelerating the epithelialization process in STSG donor sites. We conducted a pilot study to determine whether topical pirfenidone is effective in reducing total epithelialization times in STSG donor sites.

## 2. Methods

We conducted an experimental, longitudinal, prospective, and comparative study with blinded evaluations at the Hospital University “Dr. José E. González” in Monterrey, Mexico. It was designed and monitored in accordance with the Declaration of Helsinki and Good Clinical Practice as defined by the International Conference on Harmonization. The study was approved by the institutional ethics committees of our institution. All patients provided a written informed consent. The inclusion criteria included patients who required STSG with a donor site of at least 7.5  $\times$  10 cm, burn and trauma patients. The exclusion criteria comprised pregnant patients, patients with known allergy to any of the components of the formula, patients under steroids treatment and those with additional dermatological diseases. A STSG of 0.35 mm (0.014 in.) of at least 10  $\times$  7.5 cm from anterolateral aspect of the proximal thigh was obtained, using a Zimmer<sup>TM</sup> dermatome 8821-01 (Zimmer Orthopaedic Surgical Products, Ohio).

### 2.1. Randomization and allocation

Patients were randomized 1:2 in either control or treatment group using a computer generator program for this single center study. The control group comprised 9 patients in whom donor sites were covered only with non-adherent gauzes (ADAPTIC<sup>®</sup>, Systagenix, Gatwick, UK). On the other hand, treatment group comprised 14 patients in whom donor sites were covered with ADAPTIC<sup>®</sup> followed by the application of 5 ml of Kitoscell<sup>®</sup> gel over the entire area.

### 2.2. Donor site management

#### 2.2.1. Control group

As mentioned previously, donor sites were covered with a non-adherent gauze, without any secondary dressing. No further management was provided. On day 9, a 5 mm layer of petroleum jelly (Vaseline, Unilever, London, UK) was applied over the donor site and left overnight. On the following day, the ADAPTIC<sup>®</sup> was removed to assess epithelialization.

### 2.3. Treatment group

The donor site was covered with ADAPTIC<sup>®</sup> and 5 ml of Kitoscell<sup>®</sup> were distributed over the donor site area every 8 h (q-8h) for 6 days. No secondary dressing or further management were provided. On day 6, Vaseline was applied as previously

described in the control group, and the non-adherent dressing was removed on day 7. If complete epithelialization was not achieved, pirfenidone was applied q-8h daily until full epithelialization was attained.

#### 2.4. Epithelialization assessment

After the ADAPTIC<sup>®</sup> was removed, in both groups, clinical photographs of donor sites were taken for epithelialization assessment. The photographs were taken using a digital camera (Canon Power Shot SX500 IS HD 30×) with standardized photographic adjustments (distance of 30 cm, f30, 1/30 ISO 100) within an opaque box. The box was illuminated with three LED lamps (LAM-515, STEREN, Electronica Steren, Mexico City, Mexico), and the extremity was covered with a translucent screen to ensure consistent lighting conditions.

The photographs were evaluated by a plastic surgeon who was blinded to the treatment allocation. The percentage of epithelialization was calculated by analyzing the photographs of donor sites using an image software (Photoshop<sup>®</sup> CC 2014, Adobe Systems Incorporated, California). Briefly, the donor area was selected, and the total number of pixels in the selection was determined. The non-epithelialized areas in the image were then selected, and the number of pixels in this area was determined. The percentage of epithelialization was calculated by dividing the epithelialized area over the total donor surface area. Moreover, to assess the newly formed epithelium we took a skin biopsy with a 4 mm disposable biopsy punch (Miltex<sup>®</sup>, Integra LifeSciences Corporation, NJ, USA). Tissue samples were fixed by using formalin at 10% in order to obtain paraffin blocks. Afterwards, histological cuts of 4 µm of thickness were obtained by using a micrometer (RM2245, Leica, Wetzlar, Germany). Tissue samples were stained with hematoxylin and eosin (H&E) to assess the re-epithelization of the wound, the presence and amount of blood vessels, the presence of collagen, elastic fibers, hypo/hypergranulosis and hyperkeratosis. Measurements of the newly

formed epithelium were made by taking high resolutions digital images using a light field microscope Nikon Eclipse 50i<sup>®</sup> (Nikon Instruments Inc., Melville, NY, USA) and an image analysis system software Digital Sight DDS-2Mu<sup>®</sup> (Nikon Instruments Inc., Melville, NY, USA). The personnel who performed these analyses were blinded to treatment allocation as well.

#### 2.5. Pain assessment and adverse events

Pain was also assessed because Kitocell<sup>®</sup> has been reported to be uncomfortable when applied on open wounds. Pain was evaluated with a visual analog scale because it is a widely used tool that has been previously employed for similar studies [12–14]. The results were collected and analyzed. Adverse events related to the administration of pirfenidone were investigated. These evaluations encompassed clinical assessments of the wound for possible skin reaction (e.g. phototoxicity, photosensitivity, or skin rash). Also, hepatic and renal function were measured weekly to assess any possible side effect.

#### 2.6. Statistical analysis

We used frequencies with percentages for categorical variables and central tendency measures to report numerical variables. We used the Chi's square test to compare categorical variables and Student's T test for numerical variables. We took a  $p$  value  $< .05$  as statistically significant. We used SPSS version 22 (IBM Corp<sup>®</sup>, Armonk, NY, USA) for all statistical analyses and Microsoft Excel 2016 (Microsoft<sup>®</sup>, Redmont, WA, USA) to create box plots and histograms.

### 3. Results

The recruitment period was between 2013 to 2015. Of the initial 39 eligible participants 11 were excluded and a total of 28

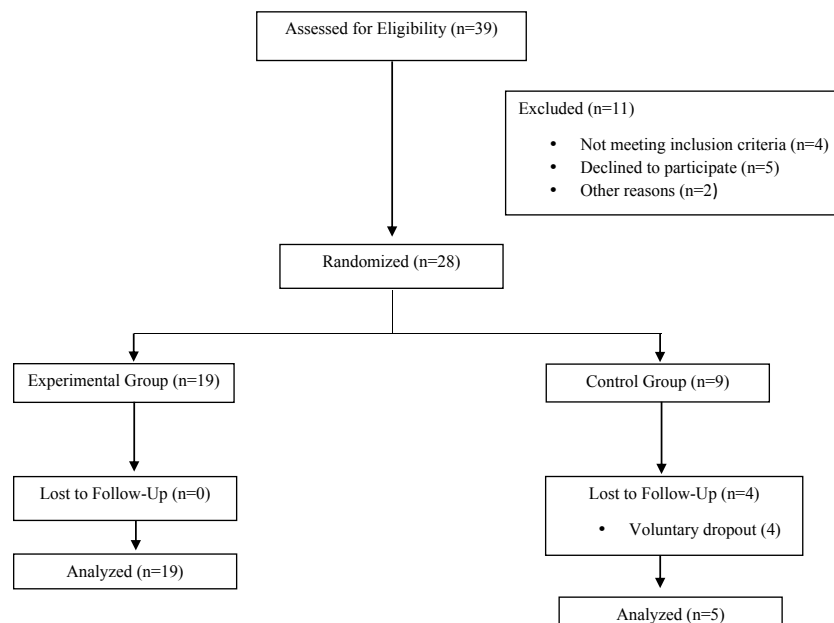


Fig. 1 – CONSORT flow diagram.

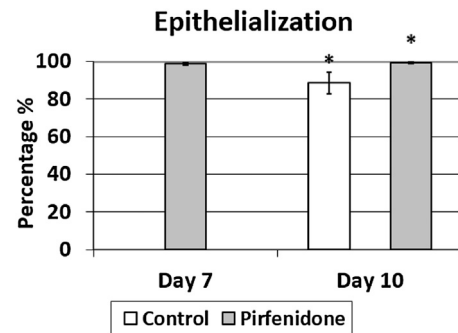
patients were randomized. Of the 28 randomized patients 19 were allocated in the experimental group and 9 in the control group, during follow-up 4 patients from the control group voluntarily dropout from the study leaving a total of 5 patients to analyze (Fig. 1). The median age of patients in the control group was 31.5 (5-73) years, whereas that of patients in the treatment group was 33.5 (9-61) years (Table 1).

The mean epithelialization rate for the control group was  $75.10 \pm 60 \mu$  at day 10, and for the pirfenidone group was at day 7,  $98.21 \pm 6 \mu$  and  $108 \pm 22$  at day 10. These differences were statistically significant ( $p=0.03$  at day 7 vs. control and  $p=0.01$  at day 10 vs. control; Figs. 2-4). The application of pirfenidone was moderately painful during the first few days, after which it was better tolerated (Fig. 5). Reported parameters of biopsies were epidermal thickness, granulosus, and the presence of collagen and elastic fibers. The treatment group had a mean epidermal thickness of  $108 \pm 28 \mu\text{m}$  at day 10, compared with  $75.10 \pm 60 \mu\text{m}$  in patients treated with fine mesh gauze (Fig. 6).

An epithelial layer was present in all biopsies, confirming that the areas deemed as “epithelialized” were indeed covered with epithelium. All samples in the treatment group ( $n=16$ ) demonstrated a normal granular layer, which is in contrast to the control group ( $n=12$ ) in which all samples demonstrated hypogranulosis (Fig. 6). Moreover, none of the patients in the pirfenidone group developed any side effect at the wound site. Also, there were no hepatic or renal alterations throughout the study.

#### 4. Discussion

Wounds produced in STSG donor sites may be severe and are often similar to superficial second-degree burns. Thus, considering the possible complications that can be caused by these wounds, these should be treated to obtain an optimal recovery [15]. It has been previously described that the ideal therapy involves using occlusive dressings because of their superiority in terms of pain relief and epithelialization times [16]. Wiechula has concluded that in the treatment of STSG donor sites, moist dressings achieve better results than dry



**Fig. 2 – Results of the photographic evaluation in donor areas. The epithelialization rate was improved in patients treated with Kitoscell at day 7 and 10 (mean values of 98.74% and 99.52%) compared to control group at day 10 (88.58%), with statistically significant results comparing both treatments at day 10 ( $p < 0.05$ ). Error bars are marked in the figure, values of 0.530543 and 0.46515 for pirfenidone at day 7 and 10, 5.754087 for control group at day 10.**

dressings in terms of healing times, pain mitigation, and infection rates [17].

Currently, multiple types of dressings with unique advantages and disadvantages are available. Studies evaluating these dressings have generally assessed parameters such as epithelialization time, pain, infection rate, ease of application, and dressing costs. Although some dressings are more efficient in reducing pain and accelerating epithelialization, costs can be a limiting factor that restricts their widespread use [18].

Among the multiple existing dressings that are used to treat donor sites, the most common is the paraffin gauze, which have numerous benefits including ease of application, low infection rate, and minimal cost. However, they have been reported to be painful and have relatively slow epithelialization times [15].

Previous studies comparing the use of other dressings with fine mesh gauzes to evaluate epithelialization times are often unreliable because of multiple variables and factors that are not always reported. Impregnated fine mesh gauzes have been shown to offer some advantages, such as the ease of use and low cost, but they have been associated with slow healing times and great discomfort in patients [16]. One relatively new therapy for STSG donor sites is platelet-rich plasma, which has been shown to accelerate epithelialization and induce angiogenesis while mitigating pain. When wound pain was assessed, this therapy was reported to be more effective when applied with fragmin and protamine [19,20]. A study conducted in Turkey compared high-valve water vapor transmission rate polyurethane film dressings (Omiderm<sup>®</sup>, Omicron Scientific, Rehovot, Israel) with the standard fine mesh gauzes in the epithelialization of STSG donor sites in diabetic patients. The results showed a mean healing time of  $13.57 \pm 4.12$  d in the Omiderm<sup>®</sup> group compared with  $18.89 \pm 5.52$  d in the fine mesh group. When assessing pain with the visual analog scale, the Omiderm<sup>®</sup> group scored a mean of 1.8, 1.2, and 0.7 and the fine mesh group scored a mean of 3.1, 5.7, and 3.5 at days 1, 5, and 7, respectively [21]. Kilinc et al. have reported a mean healing time of 16.2 d in patients treated

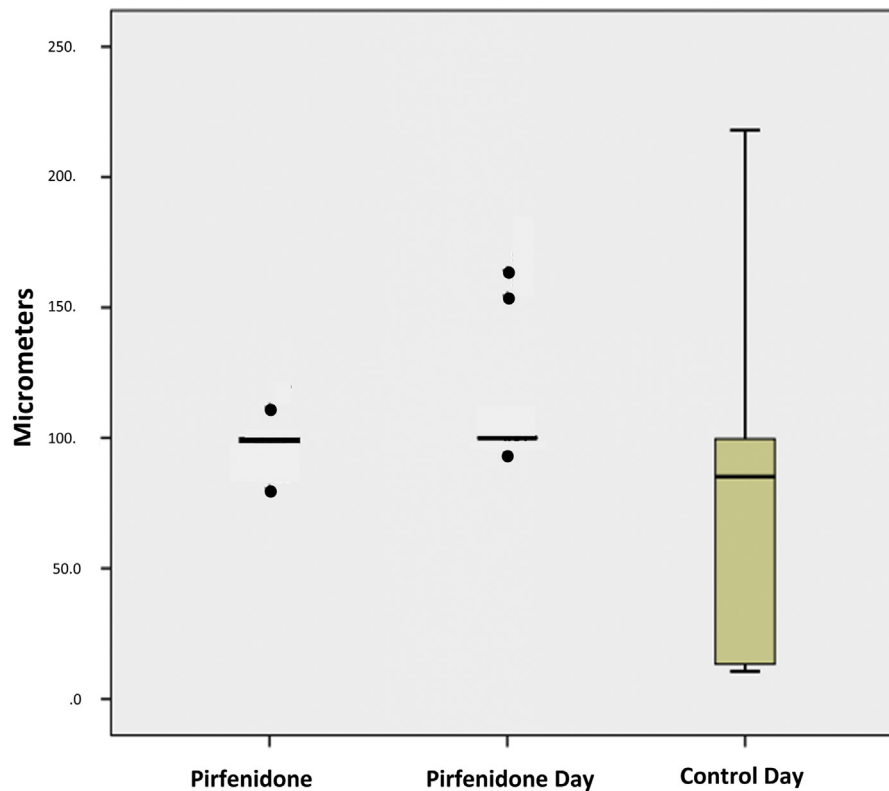
**Table 1 – Baseline characteristics of participants.**

	Control n=5	Pirfenidone n=19
Age <sup>a</sup>	21 (5-73)	28 (9-61)
Gender		
Male	4 (75)	13 (92.8)
Female	1 (25)	1 (7.1)
Etiology		
Electric	1 (20)	5 (35.7)
Flame	0 (0)	5 (35.7)
Scald	1 (20)	1 (7.1)
Friction	1 (20)	1 (7.1)
Other injuries	2 (40)	2 (14.2)

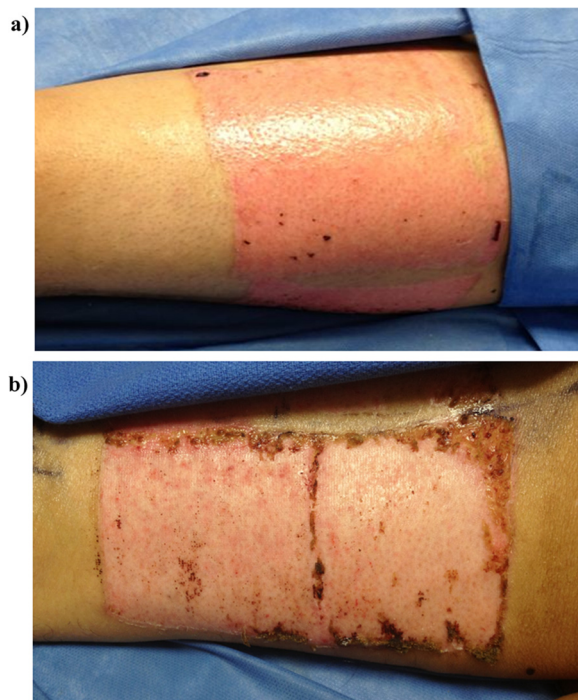
Data is presented as frequencies with percentages.

<sup>a</sup> Data is presented as median (interquartile range).





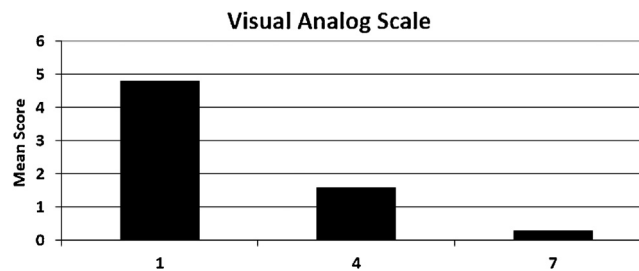
**Fig. 3 – Results by epithelial thickness.** The epithelialization thickness was improved in patients treated with pirfenidone at day 7 and 10 ( $98.21 \pm 5.78 \mu$  at day 7 and  $108 \pm 21.67$  at day 10) compared to control group at day 10 ( $75.10 \pm 59.35 \mu$ ), with statistically significant results ( $p=0.03$  at day 7 vs control and  $p=0.01$  at day 10 vs control).



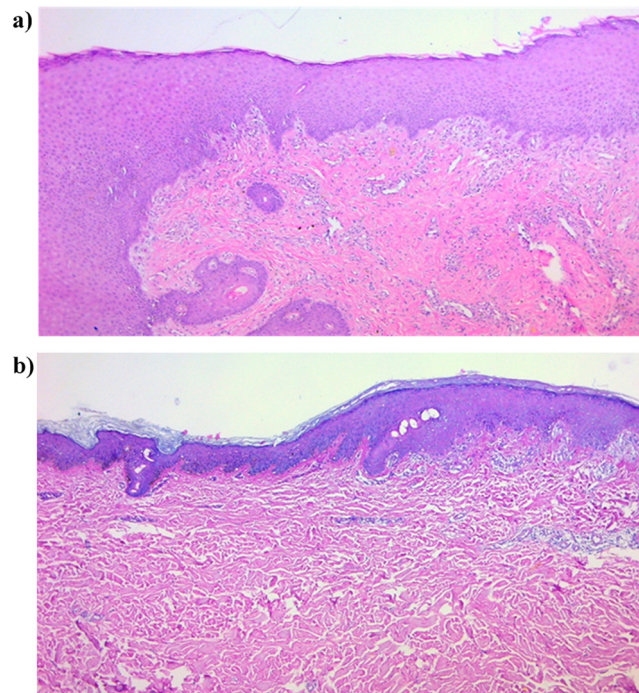
**Fig. 4 – Epithelialization at day 10. (a) Treatment group. (b) Control group.**

with fine mesh gauzes applied in a semi-open technique [16]. Uysal et al. have compared the use of oxidized regenerated cellulose (Surgicel, Ethicon, Ohio) against that of fine mesh gauzes impregnated with fusidic acid [22]. The results showed a mean epithelialization time in the semi-open groups of 6.5d for the oxidized regenerated cellulose group compared with 9.9d for the fusidic acid group [22].

In this study, we evaluated the efficacy of pirfenidone, a drug that is commonly used in the treatment of idiopathic pulmonary fibrosis because of its potent anti-inflammatory, antifibrotic, and analgesic properties [8]. Its mechanism of action revolves around the inhibition of pulmonary fibroblast proliferation and alpha-SMA mRNA expression, which results in a decreased rate of fibroblast transformation into myofibroblasts that have proliferative, migratory, and secretory properties. This reduction in myofibroblast formation translates to less aberrant scarring, which is commonly seen in this pathology [23]. Pirfenidone (Kitoscell<sup>®</sup>) is available in our country as a gel for topical application and is used to prevent and treat pathological scarring. Considering its several modulatory properties of reducing the inflammatory response with a subsequent mitigation of secondary edema which further enhances a better blood supply, we hypothesized that this gel would accelerate the epithelialization of wounds and may also be useful in the treatment of acute wounds. These effects may synergistically act by regulating wound healing and collagen production [11].



**Fig. 5 – Average scores for pain obtained using the Visual Analog Scale in patient treated with pirfenidone at day 1, 4 and 7 (scores of 4.78, 1.57, and 0.28 respectively).**



**Fig. 6 – Skin biopsy at day 10. (a) Pirfenidone group, pathology reported chronic perivascular inflammatory infiltrate associated with signs of epithelialization. Epidermis thickness of  $9.4\mu\text{m}$ . Normal granular layer. Mild hyperkeratosis. Presence of blood vessels in superior dermis. Presence of elastic and collagen fibers. (b) Control group, pathology reported epidermal thickness of  $4.9\mu\text{m}$ , hypogranulosis, mild hyperkeratosis, presence of blood vessels in superficial dermis, perivascular swelling in superior dermis, and presence of collagen and elastic fibers.**

To demonstrate that Kitoscell<sup>®</sup> could have a positive impact on the epithelialization of a wound, we decided to evaluate the acceleration of epithelialization by assessing the percentage of epithelialized areas inside STSG's donor sites. Our rationale to use this model is based on the fact that these wounds have a homogenous depth, which allowed us to compare similar wounds between the groups. In this study, we did not compare two donor sites in the same patient because of the molecular weight of pirfenidone, which is  $185.22184\text{g/mol}$  [24]. This characteristic makes it easily absorbable; therefore, a systemic effect may have been introduced causing a confounding bias in our experiment.

As shown in the results, we found that the application of pirfenidone significantly accelerated epithelialization. The group treated with Kitoscell<sup>®</sup> showed an epithelialization rate of  $98.74\% \pm 2$  at day 7, whereas the control group showed a rate of  $88.58\% \pm 14$  at day 10. Thus, patients treated with

pirfenidone exhibited a faster epithelialization than those in the control group.

In the control group, we evaluated epithelialization only at day 10 because previous studies at our institution with the standard treatment method revealed that donor sites epithelialize in a minimum of 10d; this made it ethically unjustifiable to remove the gauzes earlier. The treatment group was arbitrarily evaluated at day 7 initially, where an earlier epithelialization would be clinically significant. A posterior evaluation of both groups was performed on day 10, where we expected to see a complete epithelialization in the donor sites. Although Kitoscell<sup>®</sup> initially caused pain, around the seventh day of application a decrease in pain was observed, it was well tolerated and less painful with each subsequent application.

Strengths in our study encompass the use of photographic evaluations to assess the epithelialized areas in relation to the entire wound surface. Additionally, by using

photographic analysis we could effectively blind the observer in terms of treatment allocation and evaluation day. However, by solely using these photographic and clinical evaluations results are prone to observer dependent subjectivity that further decrease the confidence in our results. Thus, the only objective means to evaluate these areas would be wound biopsy, which unfortunately is an invasive method. Another limitation of our study is the relatively small number of patients included which may underestimate the effects of pirfenidone in healing time, however, despite this limitation we obtained a statistically significant difference in the healing time which strengthens the results of our study. Additionally, as current recommendations for the administration of topical pirfenidone is to cover the whole extension of the wound with a thin layer of gel, an important limitation of our study was that we were unable to assess the amount of pirfenidone being used.

While it would be desirable to compare pirfenidone to other available dressings, it was effective in accelerating the healing time of the STSG donor site compared with our control group. Larger, randomized, and blinded clinical trials are needed to estimate the true effect of pirfenidone in STSG donor sites. Also, we purposefully decided to administer pirfenidone topically as it is readily available in our country and the reported adverse events are fewer than the systematic administration. Nonetheless, although it would have been ideal to evaluate the differences in wound healing time between orally and topical administration, this study stands as a proof-of-concept which its observable favorable results are aimed at warranting further studies elucidating the effectiveness of pirfenidone systemically in wound healing. Even so, based on our findings, the topical administration of pirfenidone may be considered as a therapeutic use when faster healing times are required such as donor sites in burn patients.

## 5. Conclusion

Pirfenidone was effective in accelerating the epithelialization of STSG donor sites. Future studies are required to assess the quality of the obtained epithelium.

## Conflict of interests

All authors declare to have no competing interests.

## Funding

This research did not receive any specific grant from funding agencies in the public, commercial, or non-for-profit sectors.

## Authors' contributions

GAMR and JAAB conceived the research idea and design the protocol. GAMR, SB, and EGDT helped with the recruitment of

patients, performed the biopsies, recollected and analyzed the data. IMM and RFM evaluated the biopsies. GAMR and JAAB wrote the manuscript. YCG and MMGP made substantial contribution and revised the final manuscript. All authors revised and approved the definitive version of the manuscript.

## Acknowledgment

None.

## REFERENCES

- [1] Golas AR, Hernandez KA, Spector JA. Tissue engineering for plastic surgeons: a primer. *Aesthet Plast Surg* 2014;38:207–21, doi:<http://dx.doi.org/10.1007/s00266-013-0255-5>.
- [2] Adams DC, Ramsey ML. Grafts in dermatologic surgery: review and update on full- and split-thickness skin grafts, free cartilage grafts, and composite grafts. *Dermatol Surg* 2005;31:1055–67, doi:<http://dx.doi.org/10.1111/j.1524-4725.2005.31831>.
- [3] Ruszczak Z, Schwartz RA. Modern aspects of wound healing: an update. *Dermatol Surg* 2000;26:219–29, doi:<http://dx.doi.org/10.1046/j.1524-4725.2000.09215.x>.
- [4] Simizu R, Kishi K, Okabe K, Uchikawa Y, Sakamoto Y, Hattori N, et al. Recruited minced skin grafting for improving the skin appearance of the donor site of a split-thickness skin graft. *Dermatol Surg* 2012;38:654–60, doi:<http://dx.doi.org/10.1111/j.1524-4725.2011.02266.x>.
- [5] Weyandt GH, Bauer B, Berens N, Hamm H, Broecker EB. Split-skin grafting from the scalp: the hidden advantage. *Dermatol Surg* 2009;35:1873–9, doi:<http://dx.doi.org/10.1111/j.1524-4725.2009.01308.x>.
- [6] Rakel BA, Bermel MA, Abbott LI, Baumler SK, Burger MR, Dawson CJ, et al. Split-thickness skin graft donor site care: a quantitative synthesis of the research. *Appl Nurs Res* 1998;11:174–82, doi:[http://dx.doi.org/10.1016/S0897-1897\(98\)80296-6](http://dx.doi.org/10.1016/S0897-1897(98)80296-6).
- [7] Voineskos SH, Ayeni OA, McKnight L, Thoma A. Systematic review of skin graft donor-site dressings. *Plast Reconstr Surg* 2009;124:298–306, doi:<http://dx.doi.org/10.1097/PRS.0b013e3181a8072f>.
- [8] Hilberg O, Simonsen U, du Bois R, Bendstrup E. Pirfenidone: significant treatment effects in idiopathic pulmonary fibrosis. *Clin Respir J* 2012;6:131–43, doi:<http://dx.doi.org/10.1111/j.1752-699X.2012.00302.x>.
- [9] Visner GA, Liu F, Bizargity P, Liu H, Liu K, Yang J, et al. Pirfenidone inhibits T-cell activation, proliferation, cytokine and chemokine production, and host alloresponses. *Transplantation* 2009;88:330–8, doi:<http://dx.doi.org/10.1097/TP.0b013e3181ae3392>.
- [10] Armendariz-Borunda J, Lyra-Gonzalez I, Medina-Preciado D, Gonzalez-Garcia I, Martinez-Fong D, Miranda RA, et al. A controlled clinical trial with pirfenidone in the treatment of pathological skin scarring caused by burns in pediatric patients. *Ann Plast Surg* 2012;68:22–8, doi:<http://dx.doi.org/10.1097/SAP.0b013e31821b6d08>.
- [11] Cantú-Cantú MZ, Lyra-González I, Armendáriz-Borunda J. Coadjuvant treatment with surgery and pirfenidone in severe facial trauma due to dog bite. *J Craniofac Surg* 2013;24:675–8, doi:<http://dx.doi.org/10.1097/SCS.0b013e31828609cb>.
- [12] Kaiser D, Hafner J, Mayer D, French LE, Läubli S. Alginate dressing and polyurethane film versus paraffin gauze in the treatment of split-thickness skin graft donor sites: a

- randomized controlled pilot study. *Adv Ski Wound Care* 2013;26:67-73, doi:<http://dx.doi.org/10.1097/01.ASW.0000428863.34294.9d>.
- [13] Cigna E, Tarallo M, Bistoni G, Anniboletti T, Trignano E, Tortorelli G, et al. Evaluation of polyurethane dressing with ibuprofen in the management of split-thickness skin graft donor sites. *In Vivo (Brooklyn)* 2009;23:983-6, doi:<http://dx.doi.org/10.1097/00006123-200108000-00033>.
- [14] Misirlioglu A, Eroglu S, Karacaoglan N, Akan M, Akoz T, Yildirim S. Use of honey as an adjunct in the healing of split-thickness skin graft donor site. *Dermatol Surg* 2003;29:168-72, doi:<http://dx.doi.org/10.1046/j.1524-4725.2003.29043.x>.
- [15] Uygun F, Evinc R, Ulkur E, Celikoz B. Use of lyophilized bovine collagen for split-thickness skin graft donor site management. *Burns* 2008;34:1011-4, doi:<http://dx.doi.org/10.1016/j.burns.2007.12.007>.
- [16] Kilinc H, Sensoz O, Ozdemir R, Unlu RE, Baran C. Which dressing for split-thickness skin graft donor sites? *Ann Plast Surg* 2001;46:409-14, doi:<http://dx.doi.org/10.1097/0000637-200104000-00010>.
- [17] Wiechula R. The use of moist wound-healing dressings in the management of split-thickness skin graft donor sites: a systematic review. *Int J Nurs Pract* 2003;9:S9-S17, doi:<http://dx.doi.org/10.1046/j.1322-7114.2003.00417.x>.
- [18] Demirtas Y, Yagmur C, Soylemez F, Ozturk N, Demir A. Management of split-thickness skin graft donor site: a prospective clinical trial for comparison of five different dressing materials. *Burns* 2010;36:999-1005, doi:<http://dx.doi.org/10.1016/j.burns.2009.05.017>.
- [19] Takabayashi Y, Ishihara M, Sumi Y, Takikawa M, Nakamura S, Kiyosawa T. Platelet-rich plasma-containing fragmin-protamine micro-nanoparticles promote epithelialization and angiogenesis in split-thickness skin graft donor sites. *J Surg Res* 2015;193:483-91, doi:<http://dx.doi.org/10.1016/j.jss.2014.08.011>.
- [20] Kakudo N, Kushida S, Minakata T, Suzuki K, Kusumoto K. Platelet-rich plasma promotes epithelialization and angiogenesis in a split-thickness skin graft donor site. *Med Mol Morphol* 2011;44:233-6, doi:<http://dx.doi.org/10.1007/s00795-010-0532-1>.
- [21] Tan Baser N, Yuksel Barutcu A, Balci Akbuga U, Terzioğlu A, Aslan G. High-valve vapor-permeable film dressing versus fine mesh gauze dressing on skin graft donor areas in diabetic patients: a prospective randomized controlled trial. *Eur J Plast Surg* 2008;31:219-28, doi:<http://dx.doi.org/10.1007/s00238-008-0273-8>.
- [22] Uysal AC, Alagoz MS, Orbay H, Sensoz O. An alternative dressing material for the split-thickness skin graft donor site: oxidized regenerated cellulose. *Ann Plast Surg* 2006;57:60-4, doi:<http://dx.doi.org/10.1097/01.sap.0000208945.12083.59>.
- [23] Conte E, Gili E, Fagone E, Fruciano M, Iemmolo M, Vancheri C. Effect of pirfenidone on proliferation, TGF- $\beta$ -induced myofibroblast differentiation and fibrogenic activity of primary human lung fibroblasts. *Eur J Pharm Sci* 2014;58:13-9, doi:<http://dx.doi.org/10.1016/j.ejps.2014.02.014>.
- [24] Neri T, Lombardi S, Faïta F, Petrini S, Balia C, Scalise V, et al. Pirfenidone inhibits p38-mediated generation of procoagulant microparticles by human alveolar epithelial cells. *Pulm Pharmacol Ther* 2016;39:1-6, doi:<http://dx.doi.org/10.1016/j.pupt.2016.05.003>.